

# CONTINUING EDUCATION

# INSTRUMENT-BASED SCLERAL LENS FITTING

GREGORY W. DENAEYER, OD  
JASON G. JEDLICKA, OD

EDITED BY CHAD ROSEN, OD, MBA

Fourth in a series of four scleral lens CE activities for 2021

## LEARNING METHOD AND MEDIUM

This educational activity consists of a written article and 20 study questions. The participant should, in order, read the Activity Description listed at the beginning of this activity, read the material, answer all questions in the post test, and then complete the Activity Evaluation/Credit Request form. To receive credit for this activity, please follow the instructions provided below in the section titled To Obtain CE Credit. This educational activity should take a maximum of 2 hours to complete.

## CONTENT SOURCE

This continuing education (CE) activity captures key statistics and insights from contributing faculty.

## ACTIVITY DESCRIPTION

The goal of this article is to better eyecare professionals' understanding of fitting scleral lenses by using instrument-based techniques. A review of the literature will provide the reader with an improved understanding of various instrumentation, scleral lens prescriptions, and fitting techniques.

## TARGET AUDIENCE

This educational activity is intended for optometrists, contact lens specialists, and other eyecare professionals.

## ACCREDITATION DESIGNATION STATEMENT

This course is COPE approved for 2 hours of CE credit.  
COPE Course ID: 74177-CL

## DISCLOSURES

**Gregory W. DeNaeyer, OD**, has received honorarium from Contamac and consulting royalties from Visionary Optics.

**Jason G. Jedlicka, OD**, has received consulting fees from Bausch + Lomb and Oculus, instrumentation honorarium from Eaglet Eye, and remuneration from Essilor.

**Chad Rosen, OD, MBA**, editor of the continuing education series, reports no conflicts of interest.

## DISCLOSURE ATTESTATION

The contributing faculty members have attested to the following:

1. That the relationships/affiliations noted will not bias or otherwise influence their involvement in this activity;
2. That practice recommendations given relevant to the companies with whom they have relationships/affiliations will be supported by the best available evidence or, absent evidence, will be consistent with generally accepted medical practice;
3. That all reasonable clinical alternatives will be discussed when making practice recommendations.

## TO OBTAIN CE CREDIT

To obtain COPE CE credit for this activity, read the material in its entirety, and consult referenced sources as necessary. We offer instant certificate processing for COPE credit. Please take the post test and evaluation online by using your OE tracker number and logging in to [clspectrumce.com](https://clspectrumce.com).

Upon passing the test, you will immediately receive a printable, PDF version of your course certificate for COPE credit. On the last day of the month, all course results will be forwarded to ARBO with your OE tracker number and your records will be updated. You must score 70% or higher to receive credit for this activity. Please make sure you take the online post test and evaluation on a device that has printing capabilities.

## NO-FEE CONTINUING EDUCATION

There are no fees for participating in and receiving credit for this CE activity.

## DISCLAIMER

The views and opinions expressed in this educational activity are those of the faculty and do not necessarily represent the views of Michigan College of Optometry or *Contact Lens Spectrum*. This activity is copyrighted to PentaVision LLC ©2021. All rights reserved.

This activity is supported by unrestricted educational grants from ABB Optical Group and BostonSight.

CE Questions? Contact [CE@pentavisionmedia.com](mailto:CE@pentavisionmedia.com) for help.

**RELEASE DATE: NOVEMBER 1, 2021**

**EXPIRATION DATE: SEPTEMBER 9, 2024**



# INSTRUMENT-BASED SCLERAL LENS FITTING

GREGORY W. DENAEYER, OD & JASON G. JEDLICKA, OD

**M**ost scleral lenses over the last 30 years have been fit using diagnostic lens sets. This trial-and-error process is a mixture of art and science, and its efficiency is largely based on practitioner experience. Necessary scleral lens fitting objectives include adequate fluid reservoir, clearance of the limbus, and a landing zone that aligns evenly with the bulbar conjunctiva/scleral surface. One notable study has estimated that it takes a novice scleral lens fitter up to 60 cases to become proficient at fitting when using diagnostic lenses.<sup>1</sup>

Ideally, scleral lenses would be empirically fit from measurements, similar to corneal GP lenses that can be ordered for patients who have normal corneas. For GP lenses, a corneal map, generated from measurements using a topographer, can be used to align the back surface of a lens with a patient's cornea. Unfortunately, the plácido-based corneal topographers that most practitioners use in clinical practice can't measure out onto the scleral surface. Several publications have looked at the possible relationship between the cornea and sclera to determine whether corneal maps could predict scleral shape to aid scleral lens fitting. Initial pilot studies indicated that there wasn't a predictable relationship between corneal toricity and scleral shape;<sup>2-4</sup> however, recent studies reported a potential relationship, especially when corneal toricity was greater than 2.00D.<sup>5-8</sup> Additionally, the Scleral Shape Study Group found that the sclera tends to be steeper in the same meridian as the apex of corneal steepening for patients who have ectasia.<sup>9</sup> These findings give practitioners additional data that may help with selecting scleral diagnostic lenses more efficiently, but they do not allow for empirical scleral lenses fitting.

## PROFILOMETRY

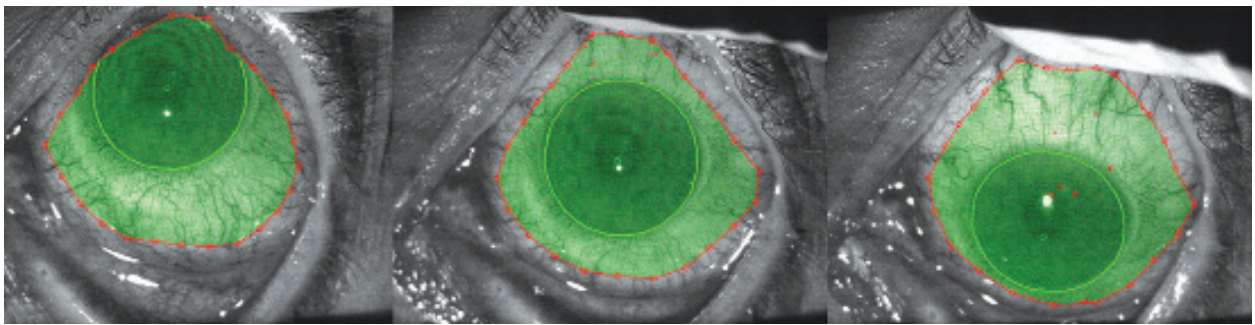
Recently, new diagnostic technology has emerged that allows practitioners to measure the anterior ocular surface beyond the cornea. Profilometers image the surfaces of the cornea and sclera, which generates maps or

three-dimensional models that can be used for shape assessment and scleral lens design. A 2017 paper from the Scleral Shape Study Group used profilometry measurements to determine scleral shape classification.<sup>8</sup> The study determined that of the eyes measured, 6% had a spherical scleral shape, 29% had a toric scleral shape, and 65% had an asymmetric scleral shape.

**Instrumentation** Three instruments are currently available that can measure corneal and scleral shape. One is a **corneoscleral topographer** that uses fluorescence detection of the ocular surface. Three separate images of the eye are then taken while patients follow a fixation target in straight, down, and up gazes (Figure 1). Taking measurements in up and down gazes is advantageous for obtaining under-the-lid measurements that can be inaccessible for some patients who have deep sockets and small palpebral apertures. The three image sets are stitched together to create a three-dimensional model with 10-micron precision that then can be used for measurements, scleral shape assessment, and customized lens design. DeNaeyer et al published a study demonstrating that 93% coverage was obtained using stitched data versus 39% for data collected only from straight gaze for a chord diameter of 16mm.<sup>10</sup>

This instrument measures sagittal height of the eye, which is one of the most critical measurements to aid in diagnostic scleral lens fitting. Sagittal height data is used to determine scleral lens parameters, such as how much sagittal depth a scleral lens needs to vault the cornea or the micron amount of toricity needed to align the landing zone. A repeatability study of this corneoscleral topographer by DeNaeyer and Sanders showed that ocular sagittal height values were repeatable to less than 50 microns in 68% of cases and to within less than 100 microns in all cases.<sup>11</sup>

The corneoscleral topographer also utilizes software that automates customization of scleral lens designs to best fit an individual eye. The data sets and design can be directly uploaded for manufacturing of branded scleral lenses that are free-form. The access that consultants have to the measurement data dramatically improves the efficiency when troubleshooting a fit lens.



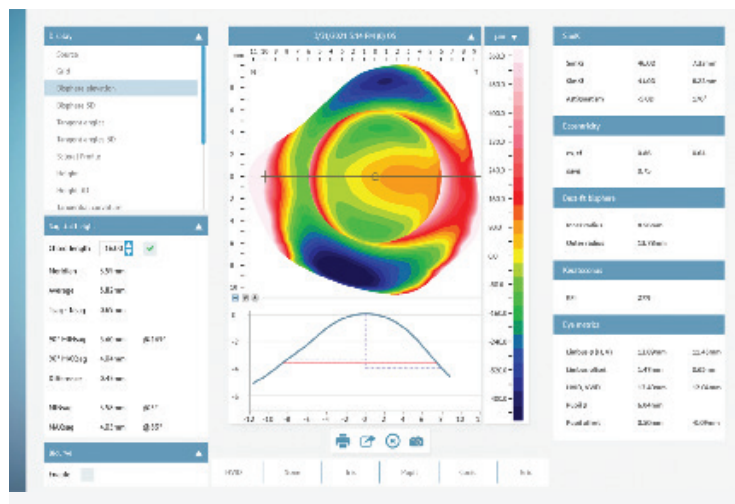
**Figure 1.** A set of up, straight, and down gazes taken with a corneoscleral topographer.

Another instrument in this category is a **scleral topographer** or profiler. It also uses fluorescein to facilitate capturing the shape of the otherwise poorly reflective sclera. This instrument takes a single image rather than using multiple stitched images. The downside is that the extent of coverage can be more limited. However, without requiring stitching, the process is more time efficient, with potentially less error in the data.

With this instrument, a lubricant is added to the eye along with the fluorescein dye to prolong the time that the dye remains on the ocular surface. With the lids held, technicians can obtain several scans in a matter of seconds. Each scan can then be reviewed for quality, and only the best scans need to be kept. This increases the odds of getting a high-quality image without needing to reapply dye and repeat.

Once an acceptable scan is obtained, the instrument can display the data in a variety of forms. The most common default map is the bisphere elevation map, in which the cornea and sclera are shown simultaneously using different reference spheres for each. This allows practitioners to get a snapshot look at the scleral shape and to determine whether it is spherical, toric, or irregular. Other useful tools are the sagittal height display menu that allows users to change the chord length and evaluate the height of the eye at any given diameter as well as to determine the amount of toricity of the sclera at a given chord (Figure 2). A final helpful tool is the data cursor, which, when hovered, provides detailed information about a given location on the map.

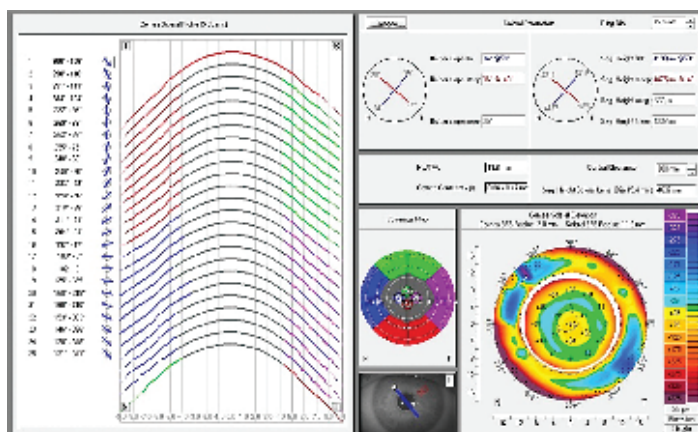
Lastly, a **corneal tomographer** can be used for scleral shape imaging when equipped with a software upgrade for this purpose. This instrument captures scleral shape data without fluorescein, using only reflective data from the scleral surface. It requires five scans wherein a central scan is followed by one of each quadrant. Obtaining



**Figure 2.** A profilometry map of a highly toric eye. The vertical meridian demonstrates a very steep profile, while the horizontal meridian is much flatter. The sagittal height menu on the left side allows you to evaluate height and toricity at any chosen chord length. The headers on the left provide data about the eye, including keratometric readings, eccentricity, and corneal diameter.

the scan requires the lids to be held; each scan is performed just like a standard tomography scan, without the need for patients to look off axis. Scans must be approved for quality and repeated if unacceptable before moving to the next scan. The benefit of this system is the multiple applications that it has beyond simply scleral topography; however, there is a higher price tag associated with these additional functions.

After selecting to scan from the software's main menu, users will capture a central scan. Once processed, the amount of data successfully acquired is displayed, along with a message from the unit letting users know whether the instrument finds the data reliable or not. The scan can be either accepted or repeated. This proceeds until all five scans are completed. The software will automatically stitch the five images into a single display map and will extrapolate data at the users' discretion out to 18mm.



**Figure 3.** Software report from a corneal tomographer. The left half shows the sagittal height of each individual cross section. The bottom right is an elevation map of the cornea and sclera. The upper right contains sagittal height data that is adjustable.

The software's report shows an elevation display map for immediate reference to cornea and scleral shape, using a bisphere display with the cornea and sclera on different reference spheres. The report provides sagittal height data at any chosen ring diameter of the flat and steep meridians, the mean sagittal height, and the amount of toricity. It also provides corneal diameter and a recommended sagittal height for a scleral lens based on the desired central clearance (Figure 3).

### INTERPRETING SCLERAL TOPOGRAPHY

The most common map to use for scleral assessment is the elevation map, which displays the shape of the sclera in terms of its elevation relative to a reference sphere. The typical scale has cooler colors representing negative elevation, or greater depression, and the warmer colors representing higher areas. This then indicates that the slope of the eye in areas that are blue, for example, are

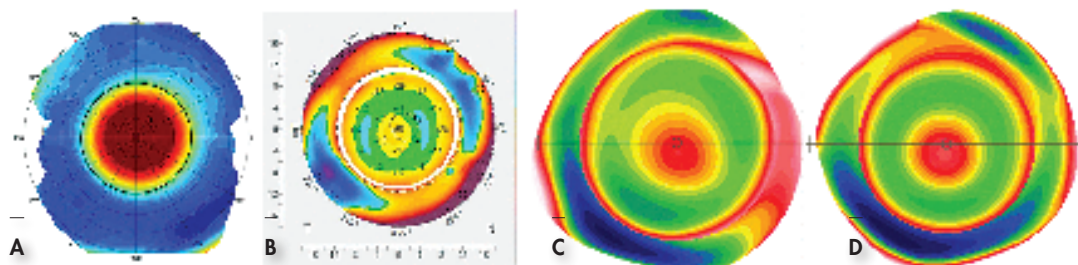
steeper and require a greater depth compared to an area in red. So, in essence, as opposed to a typical corneal curvature map, the blue areas on a scleral elevation map indicate the areas of steeper curvature, while the warmer colors are areas with less curvature change.

We can see a variety of shape patterns when interpreting a scleral map, such as spherical, regularly toric, asymmetric toric, and irregular. As mentioned, studies have demonstrated that spherical scleras are the rarest, while asymmetric scleras are the most common.

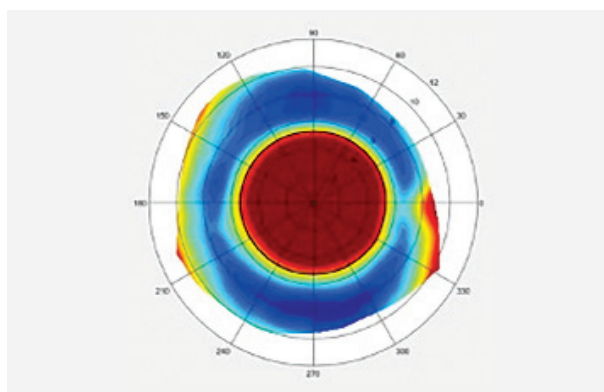
Figure 4 shows the spectrum of scleral shape patterns. Using the elevation map as a quick reference, we can immediately decide whether we need to fit someone in a spherical, toric, or quadrant-specific haptic or, in extreme cases, in a completely free-form lens. In addition, focal elevations can be seen on some maps. For example, pingueculae and filtering blebs will show up as hot spots on an otherwise cooler area of sclera (Figure 5).

### USING SCLERAL TOPOGRAPHY TO AID IN SCLERAL LENS FITTING

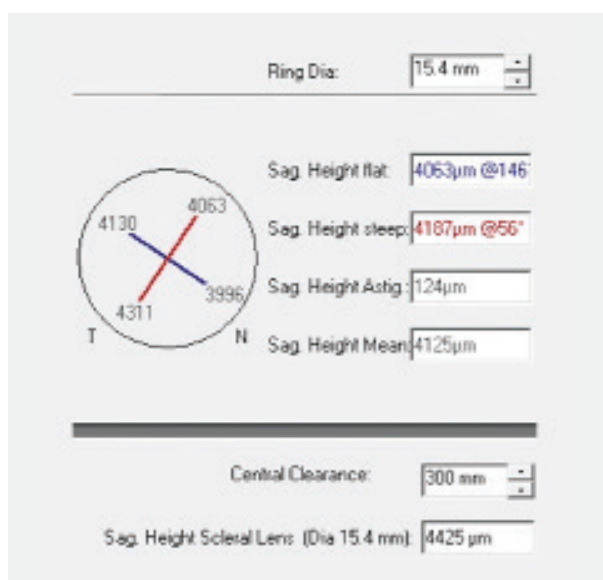
Scleral topography can assist in fitting a scleral lens in many ways, from gathering the basic shape information and letting it guide your diagnostic fitting process all the way through to allowing software to design the lens empirically based on the map. All scleral topographers will provide basic sagittal height data at a given chord as well as the amount of toricity in the sclera. If you prefer to use diagnostic lenses to fit patients, you can obtain the needed sagittal height data for selecting the lens diameter as well as obtain the toricity of the sclera at that diameter (Figure 6). Going to your diagnostic fitting set, you can then choose the closest sagittal height to your measurement and decide whether you will fit a spherical or toric haptic, then place the lens on eye. Most of the time, this



**Figure 4.** Scleral shape patterns: (A) spherical sclera, little difference in slope 360° around; (B) regularly toric, the meridian at 130° is elevated and therefore flatter in curvature, while the meridian at 40° has increased sag and therefore is steeper in curvature; (C) asymmetric toric, the meridian at 80° is steeper, but much more so in the inferior quadrant than in the superior quadrant, while the quadrant on the right is much higher compared with the quadrant on the left; (D) asymmetric, the flattest part of the sclera at 110° is opposed to a very steep aspect of the sclera inferiorly.



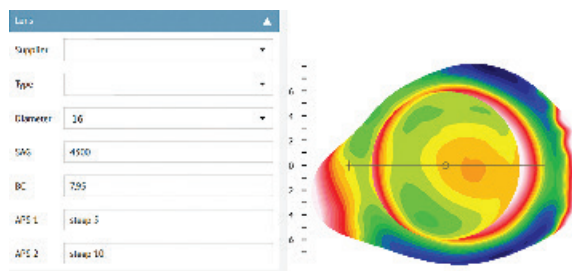
**Figure 5.** Pingecula on the nasal aspect of the sclera.



**Figure 6.** Data provided by scleral map for lens fitting. In this case, the ring diameter has been set to 15.4mm to fit a 15.4mm lens. At this diameter, the ideal lens should have a sagittal height of 4,425 microns and 124 microns of landing zone toricity.

initial lens will be close enough to an ideal fit that you can simply note your desired adjustments, over-refract, and order. Thus, even when diagnostically fitting, scleral mapping can save chair time as well as create a favorable impression with the patient regarding how efficient the process is.

Some scleral topographers have software that is or can be integrated with the instrument to aid in fitting as well. These applications will either provide you with the ideal lens parameters—such as sagittal height, diameter, and peripheral curves—and allow you to order (Figure 7), or they can integrate with labs to send that data directly to the lathe for direct manufacturing. In some instances, if the GP base curve is known and the power information



**Figure 7.** Lens fit parameters for the map on the right. If the needed power is known through prior lens orders, the lens can be ordered empirically without apply a diagnostic lens.

already determined, practitioners can order an initial lens without using a diagnostic set at all.

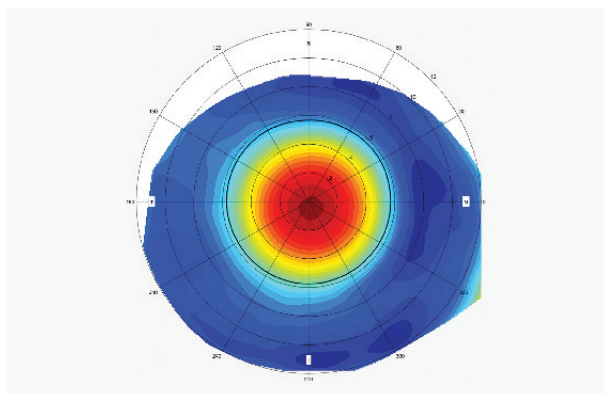
When a truly customized lens is needed due to significant scleral irregularity, scleral shape data can be uploaded directly to an application that will design a completely custom lens from the map. These apps have a link in the device for practitioners to begin the creation of a completely free-form lens for an individual eye with the click of a button. These lenses come at a price, but when faced with a highly irregular eye shape, practitioners have the capability to create a multizone lens design made to fit a particular eye as precisely as possible.

### CASE STUDIES IN SCLERAL LENS FITTING

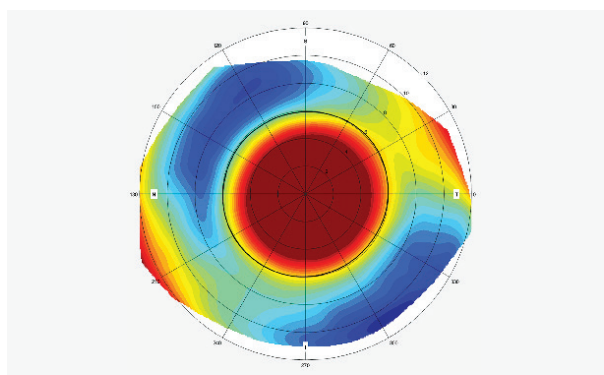
**Case 1** A 52-year-old male who had granular corneal dystrophy reported for scleral lens evaluation. He was currently wearing bandage soft contact lenses on a continuous wear basis for improved vision and to prevent recurrent erosions. The patient was referred from his corneal specialist to see whether scleral lenses could improve his vision. The patient was most anxious about passing his driver's license test. His visual acuity with soft lenses was OD 20/50 and OS 20/80.

Slit-lamp examination showed moderate granular dystrophy changes in both eyes. A corneoscleral topography measurement of both eyes was taken after the patient removed his soft lenses the night before. Scleral elevation maps showed that his right sclera had a spherical shape (Figure 8), and his left sclera had 255 microns of oblique scleral toricity (Figure 9). Keep in mind that the cooler or blue colors typically represent areas of relative steepness or increased sagittal height, and the warmer or red colors represent relative flattening or decreased sagittal height in elevation maps.

With no significant asymmetry of either sclera, this patient can be fit with a standard scleral lens design using the maps to guide diagnostic lens fitting. Scleral diagnostic lenses with spherical landing zones for the right eye and toric landing zones for the left eye can be applied to determine the desired fluid reservoir and power. Knowing the exact scleral shape prior to starting diagnostic lens



**Figure 8.** Scleral elevation map shows that the Case 1 patient's right sclera has a spherical shape.



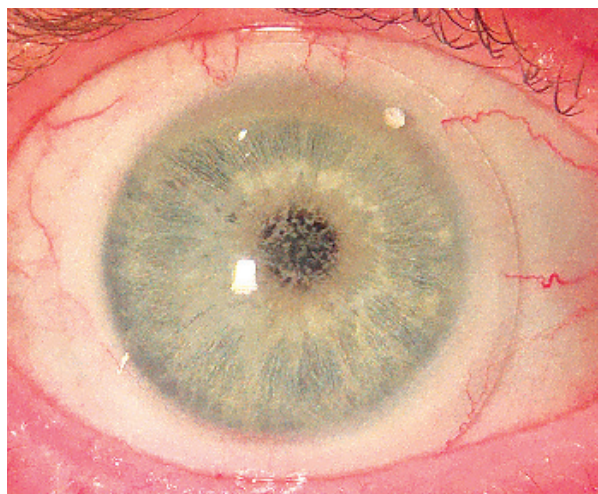
**Figure 9.** The patient's left sclera has 255 microns of oblique scleral toricity.

fitting significantly improves efficiency, especially in this case, as the patient's scleral shape is different between the right and left eyes. The dispensed 16mm scleral lenses had landing zones that aligned with the bulbar/conjunctival scleral surfaces with an adequate fluid reservoir (Figure 10). The patient's visual acuity measured 20/40 for both the right and left eyes.

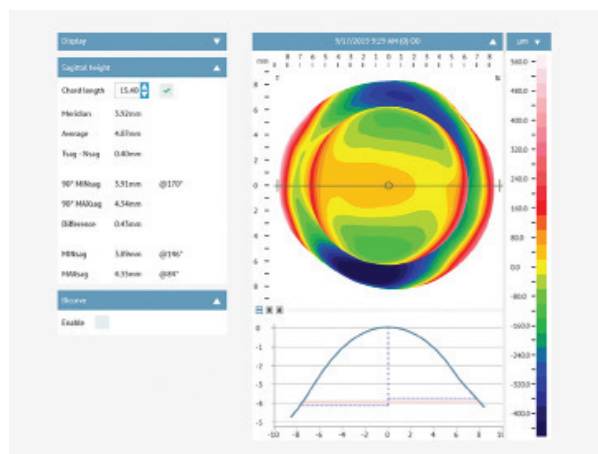
**Case 2** A 27-year-old female presented for an eye exam wearing glasses, as she had been growing more intolerant of her GP lenses, which caused her eyes to be red and dry. She had tried soft toric and hybrid lenses in the previous two years without success. She preferred contact lens wear over glasses due to her high hyperopic and toric prescription, and she was looking for new options.

Her examination revealed an Rx of +7.50 -4.00 x 001 OD and +7.50 -3.50 x 003 OS, correcting to 20/25 in each eye. Slit-lamp examination revealed vascularized limbal keratitis OD and OS. After discussing her options, which included scleral lenses, she opted to try sclerals to see whether they could give her the vision and comfort that were lacking in the other options she had tried.

Profilometry performed on each eye demonstrated both corneal and scleral toricity in a with-the-rule pattern



**Figure 10.** The dispensed 16mm scleral lenses had landing zones that aligned with bulbar/conjunctival scleral surface with an adequate fluid reservoir.



**Figure 11.** Profilometry of the right eye. The map shows a significant with-the-rule toric pattern. The data shows an average sagittal height of 4.07mm (4,070 microns). The difference value of 0.43mm indicates 430 microns of toricity.

(Figure 11). Based on her map and data, which reported an average sagittal height of 4,070 microns at the 15.4mm chord diameter and 430 microns of toricity, a 7.50mm BC, 15.4mm diameter, 4,400 sagittal height lens with toric haptics (120 microns) and an Rx of -2.00D was applied to her right eye. The lens demonstrated good central vault of approximately 350 microns at application, good visual outcome through an over-refraction (+7.50 = 20/20<sup>-</sup>), and mild misalignment of the landing zone, as would be expected given the significant toricity in the sclera. Her initial response to the lens was very positive despite the edges not being optimal.

We ordered the lens in a 7.50mm BC, 15.4mm diameter, +6.25D Rx, 4,400 sagittal height, and peripheral

curves 150 microns flat in the horizontal meridian x 270 microns steep in the vertical meridian (420 microns total toricity) to approximate the toricity measured on the map. The ordered lens demonstrated good central clearance (Figure 12), and good scleral alignment (Figure 13).


This case illustrates how a scleral topography and the associated data can be used to help decide upon a proper diagnostic lens, and then further refine the fit once diagnostic fitting has been completed.

**Case 3** A 61-year-old male patient reported for contact lens evaluation of his right eye. He was already successfully wearing a soft contact lens for his left eye. The patient's right eye had two previous surgeries for pterygium removal and amniotic graft. The patient's uncorrected right eye visual acuity was 20/50 (doubled). Manifest refraction OD was +3.75 -4.75 x 002, 20/30. Slit-lamp examination showed corneal scarring and persistent nasal and temporal pterygium.

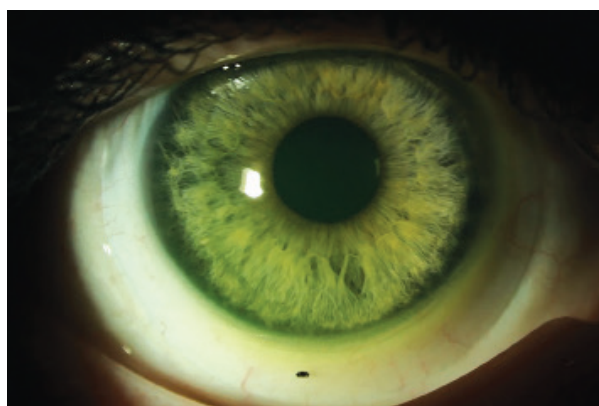
An attempt to fit his right eye with a custom soft toric contact lens was initially successful, but he eventually failed because of poor vision. The patient was then advised that his best option would be a scleral lens that would provide lens stability and improved visual acuity. A scleral elevation map revealed 508 microns of with-the-rule scleral toricity, with asymmetry that corresponds to the eye's residual pterygium (Figure 14). The fitting process using diagnostic lenses for a back-surface landing zone design would be a challenging two-step process: first matching scleral toricity and then creating localized vaults to avoid impingement. To efficiently fit this eye, a free-form customized lens was designed and manufactured from corneoscleral topography (Figure 15). The landing zone of the resulting 16.5mm scleral lens lands evenly on the conjunctival/scleral surface without compression, impingement, or edge lift (Figure 16). There was an adequate amount of fluid reservoir, and the patient's visual acuity was 20/30. Remarkably, the patient was successful with the first lens, and no adjustments were needed. This case is a great example of the advantage of customizing lens design directly from corneoscleral measurement.

**Case 4** A 61-year-old female presented for an annual exam and scleral lens evaluation. She had been in scleral lenses for the last two years and was satisfied with her right lens. However, her left lens did not provide the all-day comfort that she experienced with the right lens and would fog after a few hours of wear. She was looking for ways to improve this left lens, as she would often only wear the right lens due to the left lens issues. After evaluating her lens fit, noting debris flowing through a misaligned landing zone and finding no compelling reason for the lack of comfort, we offered to refit this left eye in a free-form lens design, hoping for better alignment and comfort.

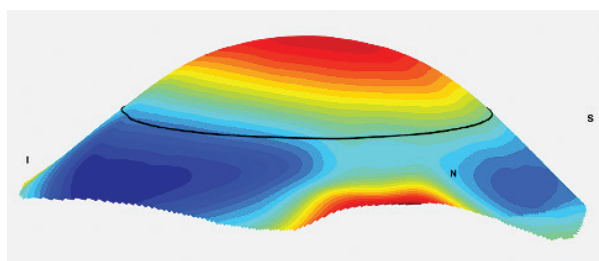
Because she had not worn the left lens for several days prior to the appointment, we were able to obtain scleral




**Figure 12.** Central vault through the ordered 4,400 sagittal height lens OD of Case 2 patient.



**Figure 13.** Overview of ordered lens OD for Case 2.

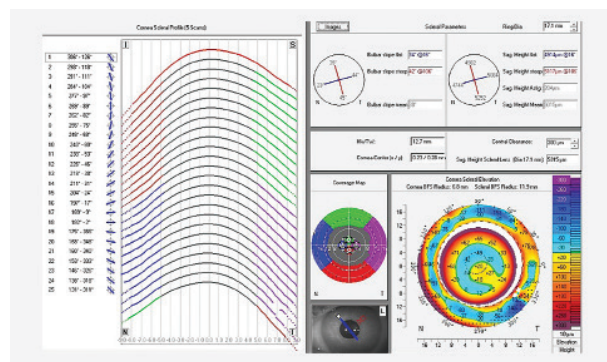
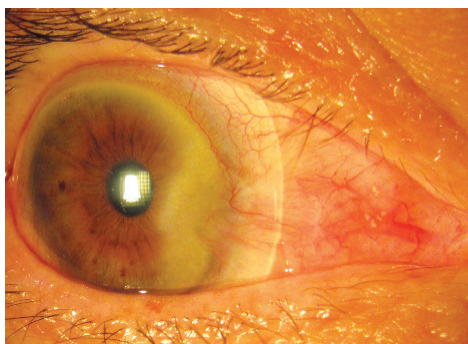


**Figure 14.** Case 3 patient's right eye scleral elevation map with scleral toricity and asymmetry.

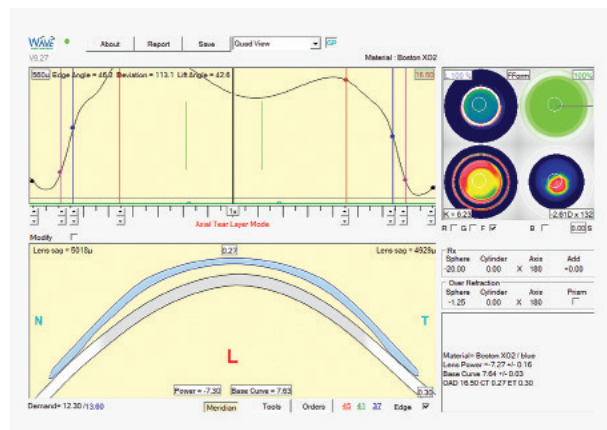


**Figure 15.** A free-form customized lens was designed and manufactured from corneoscleral topography.

**Figure 16.** Free-form 16.5mm scleral lens for the Case 3 patient's right eye.



**Figure 17.** Scan of the Case 4 patient's left eye. The elevation map shows a quadrant-localized area of elevation between 1 o'clock and 3 o'clock, which may have been the reason for the discomfort and debris flow.

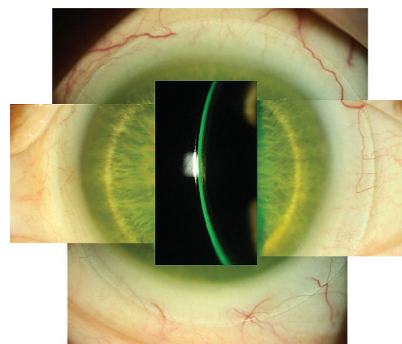


**Figure 18.** Software design box for Case 4 patient's left lens.

topography (a minimum of 48 hours out of lenses prior to mapping is generally preferred). The map did indicate a quadrant-specific effect of her sclera, with an area of higher elevation between 1 o'clock and 3 o'clock, which may have been the reason for the issues experienced with her previous lens (Figure 17).

We designed a lens with a tomographer's integrated software that uses the map to generate a free-form lens design. Prescribers have some control over the

**Figure 19.** Scleral lens on Case 4 patient's left eye. This lens was the initial lens designed entirely from scleral topography. The central clearance was measured at 300 microns 30 minutes after application, and the scleral zone showed proper alignment 360° around.



design, such as determining the desired corneal vault and adjusting the fit once the lens is designed; but, allowing the software to have control of the base curve, limbal clearance, and scleral landing zones is the best initial approach (Figure 18). Knowing the needed prescription based upon her prior scleral lens power and base curve, this was added to the software for lens power determination without having to apply a lens at all in office.

The lens was electronically ordered and arrived one week later. It was dispensed a few days later and provided good initial comfort and vision. The central clearance was measured at 300 microns 30 minutes after application, and the scleral zone showed proper alignment 360° around (Figure 19). Over the next several weeks, the patient was able to wear the lens without the comfort issues of the previous lens and without the same level of fogging that she had previously experienced.

## CONCLUSION

The popularity of scleral lenses has propelled the development of technology to improve both fitting efficiency and success. Metrics taken from profilometers can help practitioners customize lenses for optimal fitting. For more challenging fits, free-form lens designs can be used to successfully fit eyes that have even the highest amounts of scleral asymmetry.

*For references, please visit [www.clspectrum.com/references](http://www.clspectrum.com/references) and click on document #312.*

**Dr. DeNaeyer** practices at Arena Eye Surgeons in Columbus, OH. He is a shareholder of Precision Ocular Metrology LLC, has financial interest in Visionary Optics' scleral lenses, is a consultant to Visionary Optics, and has received lecture or authorship honoraria from Contamac. Contact him at [gdenaeyer@arenaeyesurgeons.com](mailto:gdenaeyer@arenaeyesurgeons.com).

**Dr. Jedlicka** is the chief of cornea and contact lens service and a clinical professor at Indiana University's School of Optometry. Dr. Jedlicka reports remuneration and honoraria from Bausch + Lomb, Oculus, and Eaglet Eye, and remuneration from Essilor.